

A Potential New Technique to Estimate the Origins of Focal Atrial Tachycardias From 12-Lead Electrocardiograms

Charles F. Babbs^{1,*}

1. Weldon School of Biomedical Engineering, Purdue University, West Lafayette, Indiana, USA

ABSTRACT

Background: This brief report presents a potential new technique for locating the sites of origin of focal atrial tachycardias from standard 12-lead electrocardiograms.

Methods: Estimated P wave vector coordinates are derived from leads I, aVF, V₁ and V₂, and mapped to a three dimensional coordinate system in space. A simple graphical method is used to find the back projection of the P wave vector onto the surface of atrial muscle to estimate the most likely site of origin of the tachycardia.

Results: Graphical back projection correctly identified foci of atrial tachycardias in 19 of 19 cases described in the most complete available published study.

Conclusions: Clinical studies are indicated to validate this simple method for initial noninvasive evaluation of candidates for ablation therapy.

Corresponding Author: Charles F. Babbs, MD, PhD, Purdue University, 206 S. Martin Jischke Drive, West Lafayette, IN 47907-2032, Fax: 765-494-1193, Telephone 765-494-2995, E-mail: babbs@purdue.edu

Academic Editor: Osmar Centurion, Professor of Medicine. Asuncion National University. Cardiology Division. First Department of Internal Medicine. Asuncion. Paraguay

Citation: Charles F. Babbs (2016) A Potential New Technique to Estimate the Origins of Focal Atrial Tachycardias from 12-Lead Electrocardiograms. Journal Of Hypertension And Cardiology - 2(1):17-22. <https://doi.org/10.14302/issn.2329-9487.jhc-16-931>

Keywords : Ablation, algorithm, foci, supraventricular tachycardia, vector

Received : Jan 13, 2016; **Accepted :** May 27, 2016; **Published:** Jun 02, 2016;

Introduction

Unifocal atrial tachycardia is an uncommon form of supraventricular tachycardia, often resistant to drug therapy, for which percutaneous radiofrequency catheter ablation is an effective treatment option.^{1,2} Anatomic localization of the earliest activation site is important for effective targeting of ablation. Previous workers have proposed that analysis of P wave morphology in the standard 12-lead electrocardiogram may be a useful initial step in predicting the origin of an atrial tachycardia³⁻⁶. The present study takes a fresh look at this problem to determine if better localization is possible when information from multiple electrocardiographic leads is combined in a spatial vector analysis⁷. Preliminary studies in computational models of impulse propagation in the atria and the resulting body surface electrocardiographic potentials were done, similar to previous work on ventricular pacing.^{8,9} These studies suggested the following scheme for localizing initial atrial activation sites in a given patient.

Methods

A three dimensional, orthogonal (x,y,z) coordinate system is defined with its origin located in the middle of the atrial septum, the x-axis pointing toward the left, y-axis pointing toward the feet (inferiorly), and z-axis pointing toward the sternum (anteriorly). A three dimensional P wave vector is defined by the amplitudes of the P wave at its midpoint in the time domain for standard Leads I, aVF, V₁, and V₂. The x coordinate of the P vector is the P wave amplitude in Lead 1. The y coordinate of the P vector is the P wave amplitude in Lead aVF. The z coordinate of the P vector is the average of the P wave amplitudes in Leads V₁ and V₂. For easy paper-and-pencil analysis corresponding two dimensional vectors are drawn in three planes: the Lead I vs. aVF (xy or frontal) plane, the Lead I vs. V₁₂ (xz or horizontal) plane, and the V₁₂ vs. aVF (zy or sagittal) plane, as shown in Figure 1. The legend of Figure 1

describes a detailed example of the method for representative Case 6 in Table 1. In brief, an imaginary line is back-projected in each plane along the axis of each two dimensional vector through the origin to a point intersecting simple anatomic sketches of the left and right atria, which were originally created from inspection of atrial anatomy in CT scans of normal human hearts. The consensus intersection of the back projection with the atrial wall in three dimensions gives the putative origin of the atrial beat. If a back projection intersects more than one point on an atrial wall in a particular plane, the ambiguity is resolved by finding the one site that best fits all three projections. Only the angles or directions of the vectors and the relative sizes and shapes of the atrial chambers are critical. Plotting of the vectors can be done in any convenient units, such as millivolts or "boxes" on a standard strip chart record of the electrocardiogram. The vectors can be drawn to any consistent scale of length, and the atrial sketches can be drawn to any convenient size.

Results

To explore the potential utility of this approach, the published data in Figures 2, 3, and 5 of the study by Kistler et al.⁵ were re-analyzed using P vector back projection. This study described 12-lead P wave morphologies in patients undergoing successful radiofrequency ablation. Actual sites of earliest endocardial activation were determined by Kistler et al. using intracardiac electrodes and point mapping of the times of onset of local electrograms relative to the body surface P wave. Full 12-lead electrocardiograms were provided for 19 representative cases. Figure 1 shows the graphical, back projection analysis of a typical case. Summary results for all 19 cases are shown in Table 1. In 19/19 cases the back projection method gave good localization ("hit") within approximately 1 cm of the actual site of first activation.

Figure 1. Reconstruction of the atrial activation site (star) by back projection in three planes. The common origin of the Lead I, aVF, V₁₋₂ (or x,y,z) coordinate system is located in the middle of the interatrial septum. Arrows on axes indicate positive directions from the origin. The tail of each vector is located at the origin. The arrow head of each vector is located at a point defined by the P wave amplitudes in Leads I, aVF, and V₁₋₂, as listed in Table 1 for Case 6. In this particular example P wave vectors (thick arrows) are constructed from the origin in each plane, as follows. Frontal plane (top): Lead I, 0; aVF, -4; vector points toward the head. Horizontal plane (middle): Lead I, 0; average of V₁ and V₂, -2; vector points toward the back. Sagittal plane (bottom): average of V₁ and V₂, -2; aVF, -4; vector points toward the back shoulder. An imaginary line is back projected from the head of each vector, through the tail of the vector at the origin, until it intersects with the superimposed sketch of the atrial wall (intersection point in three dimensions indicated by stars). This point of intersection is the putative electrophysiological origin of the tachycardia. RA right atrium; LA left atrium. In this case the actual source was in the low tricuspid annulus, which is inferior and anterior to the midpoint of the interatrial septum.

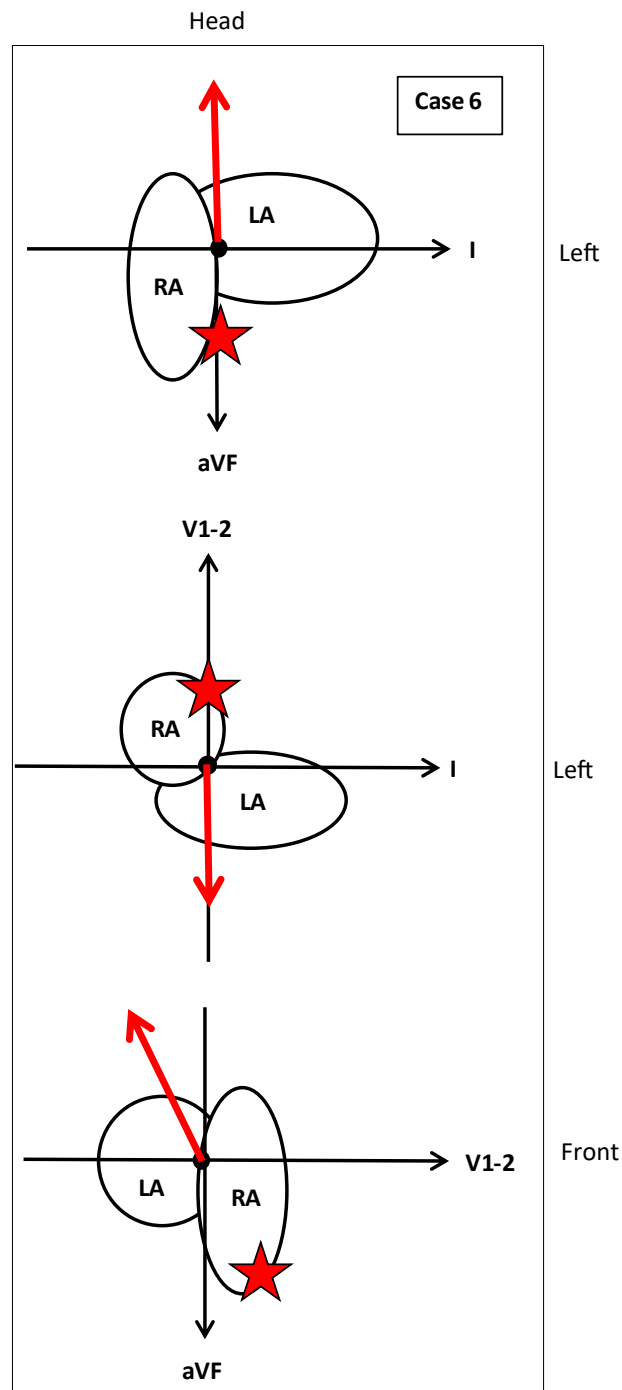


Table 1: Application of graphical back projection to 12-Lead ECG's in patients with verified sources of atrial tachycardias (Kistler et al.⁵).

Case #	P-vector coordinates (arbitrary units)			Indicated location	Actual Location	Result
	I	aVF	V1-2			
Figure 2 valve ring sites						
1	0	-4	-2	Right inferior anterior	Right posterior TV	hit
2	0	0	-2	Right anterior superior	Right anterior TV	hit
3	-1	1	3	Left superior posterior	Left lateral anterior MV	hit
Figure 3 RA sites						
4	0.5	4	0	Right superior	High crista terminalis	hit
5	1	-0.5	0	Right inferior middle	Low crista terminalis	hit
6	0	-4	-2	Right inferior anterior	Low tricuspid annulus	hit
7	0	0	0	Mid septum	Perinodal	hit
8	0.5	1	0	Superior septum	Right septal	hit
9	0.2	0.2	-1	Right anterior superior	Right atrial appendage	hit
10	0	-1	0.5	Left +/-posterior Inferior	CS os	hit
Figure 4 LA sites						
11	1	3	1	Left superior septum	Right superior pulmonary vein	hit
12	1	0	2	Left posterior middle	Right inferior pulmonary vein	hit
13	0	0.5	2	Left superior posterior	Left superior pulmonary vein	hit
14	0	0	1	Left posterior middle	Left inferior pulmonary vein	hit
15	-0.5	0.5	2	Left posterior superior	Mitral annulus	hit
16	-1	-2	2	Left inferior posterior	CS body	hit
17	-1	3	1	Left superior posterior	Left atrial appendage	hit
Figure 5						
18	1	2	0	Right superior septum	Right superior pulmonary vein	hit
19	1	3	1	Right superior posterior	High crista terminalis	hit

Discussion

The use of P wave morphology in the standard 12-lead electrocardiogram to predict the origins of atrial tachycardias is not new. In 1975 MacLean and coworkers³ paced hearts of 69 patients following open-heart surgery at one of 12 selected atrial sites to study the resulting P wave polarity and P wave morphology, which were variable and appeared to have limited usefulness in locating origins of ectopic atrial beats. Later, however, Tang et al.⁴ examined P wave configuration associated with clinical episodes of automatic atrial tachycardia to differentiate ectopic foci originating in the left atrium or in the right atrium on the basis of standard electrocardiographic findings. They found that a positive or biphasic P wave in Lead aVL predicted a right atrial focus with 88% sensitivity and 79% specificity. A positive P wave in Lead V₁ predicted a left atrial focus with 93% sensitivity and 88% specificity. Further, Leads II, III and aVF provided clues for differentiating superior from inferior foci. Kistler et al.⁵ developed a more complex P wave algorithm in the form of a branched decision tree based on findings from 130 atrial tachycardias. This algorithm correctly localized the focus in 93 percent of cases. Tada et al.⁶ described a similar decision tree algorithm to predict the foci of right atrial tachycardias on the basis of the P wave configuration in a 12-lead electrocardiogram.

The proposed graphical, back projection method is simple, intuitive, and vector based. It aggregates information from multiple electrocardiographic leads. It can be applied to single beats and thus can, in principle, distinguish between single and multiple foci. The method is relatively low in cost and may be useful for initial prediction of the origins of atrial tachycardias as a guide to subsequent endocardial mapping and radiofrequency catheter ablation.

There are, however, some important assumptions which may prove to be significant limitations. One assumption is that that impulse propagation from a source is directionally uniform rather than taking preferential intra- and interatrial conduction routes. The effects upon P wave morphology from septal activation are ignored, as is the presence of atrial structural disease. The presented technique applies to the patients with intact atria and may not apply to atrial tachycardias in which atrial activation sequence is altered because of prior atrial ablation or extensive scarring. Further, the present study is retrospective in nature.

References

1. Walsh EP, Saul JP, Hulse JE, Rhodes LA, Hordof AJ, Mayer JE, Lock JE. Transcatheter ablation of ectopic atrial tachycardia in young patients using radiofrequency current. *Circulation*. 1992;86:1138-1146
2. Kistler PM, Sanders P, Fynn SP, Stevenson IH, Hussin A, Vohra JK, Sparks PB, Kalman JM. Electrophysiological and electrocardiographic characteristics of focal atrial tachycardia originating from the pulmonary veins: Acute and long-term outcomes of radiofrequency ablation. *Circulation*. 2003;108:1968-1975
3. MacLean WA, Karp RB, Kouchoukos NT, James TN, Waldo AL. P waves during ectopic atrial rhythms in man: A study utilizing atrial pacing with fixed electrodes. *Circulation*. 1975;52:426-434
4. Tang CW, Scheinman MM, Van Hare GF, Epstein LM, Fitzpatrick AP, Lee RJ, Lesh MD. Use of p wave configuration during atrial tachycardia to predict site of origin. *J Am Coll Cardiol*. 1995;26:1315-1324
5. Kistler PM, Roberts-Thomson KC, Haqqani HM, Fynn SP, Singarayay S, Vohra JK, Morton JB, Sparks PB, Kalman JM. P-wave morphology in focal atrial tachycardia: Development of an algorithm to predict

- the anatomic site of origin. *J Am Coll Cardiol.* 2006;48:1010-1017
6. Tada H, Nogami A, Naito S, Suguta M, Nakatsugawa M, Horie Y, Tomita T, Hoshizaki H, Oshima S, Taniguchi K. Simple electrocardiographic criteria for identifying the site of origin of focal right atrial tachycardia. *Pacing Clin Electrophysiol.* 1998;21:2431-2439
 7. Grant RP. *R.P. Grant's clinical electrocardiography: The spatial vector approach.* New York: McGraw-Hill; 1957.
 8. Babbs CF. Optimizing electrode placement for hemodynamic benefit in cardiac resynchronization therapy. *Pacing Clin Electrophysiol.* 2012;35:1135-1145
 9. Babbs CF. Quantitative prediction of body surface potentials from myocardial action potentials using a summed dipole model. *Cardiovascular engineering (Dordrecht, Netherlands).* 2009;9:59-71